

Small Gauge Pars Plana Vitrectomy

Rupan Trikha, Nicole Beharry and David G. Telander
Retina Consultants, Little Silver, NJ
University of California, Davis Medical Center
 USA

1. Introduction

Although the history of ophthalmic surgery can be dated back thousands of years with operations to treat cataracts, surgery involving the vitreous cavity has only been reported for less than 50 years. The initial description of major vitreous surgery was introduced by David Kasner in 1969 (Kasner, 1969). He described excision removal of the vitreous using a sponge and scissors, under an open sky technique for removal of dense vitreous opacities secondary to amyloidosis. The major problems with this technique including the need for a corneal transplant, lack of control of intraocular pressure (IOP) during surgery, and significant vitreous traction during removal, were addressed by the development of closed intraocular vitreous surgery.

2. Historical perspective

Pars Plana Vitrectomy (PPV) was first developed in 1970 by Robert Machemer. This novel technique provided a closed system for surgical removal of vitreous with control of IOP. The initial device was a 17-gauge (1.42 mm) instrument that combined a vitreous cutter, infusion, and aspiration, and utilized 2.3 mm scleral incision (Fabian & Moisseiev, 2011). O'Malley and Heintz separated the components of vitreous cutting, infusion, and illumination and developed the first 20-gauge, 3-port vitrectomy system (O'Malley & Heintz, 1975). Improvements in technique and instrument design quickly led to the development of the three port vitrectomy system, with lightweight, reusable, pneumatic and electric cutters. For over thirty years, PPV was performed using a 20-gauge, three port system for nearly all vitreoretinal surgery.

As 20-gauge PPV became more widely used, a number of complications became apparent. A major problem was the development of iatrogenic retinal breaks, specifically those at the sclerotomy site. This was felt to be related to repeated passage of instruments through the sclerotomy and vitreous base, with resultant retinal traction and tear formation. Machemer and Hickingbotham introduced a 20-gauge cannula system that was inserted into the sclerotomy for the duration of the surgery, allowing for easier passage of instruments and reducing traction at the vitreous base (Machemer & Hickingbotham, 1985). As experience with 20-gauge PPV increased, a variety of self-sealing 20-gauge incisions were developed to help reduce surgical time, and to improve intraoperative IOP control (Hilton, 1985; Jackson, 2000). As refinements in 20-gauge vitrectomy continued, smaller gauge systems were developed.

The initial description of small gauge vitrectomy, preceded its adoption by many years. The initial set of 25-gauge instruments developed by de Juan and Hickingobtham contained only a pneumatic vitrector, scissors, and a membrane removal instrument for use in pediatric eyes (De Juan & Hickingobtham, 1990). A 23-gauge vitrectomy probe was introduced in 1990 by Peyman, although its intended application was limited to vitreous and retinal biopsy (Peyman, 1990). Small gauge pars plana vitrectomy was popularized by Gildo Fujii who introduced a sutureless, transconjunctival, 25-gauge PPV system for use in a variety of surgical cases in 2002 (Fujii et al., 2002). Two years later, Dutch Ophthalmic Research Center (DORC) working with Klaus Eckardt presented the first 23-gauge vitrectomy system (Eckardt, 2005). Alcon laboratories subsequently developed a single step 23-gauge vitrectomy system. The exploration of yet smaller gauge instruments continued with the introduction of a 27-gauge vitrectomy system in 2010 by Oshima (Oshima et al. 2010).

Since the initial introduction, small-gauge vitrectomy has seen tremendous growth in popularity amongst retinal surgeons. According to the Preference and Trends (PAT) survey conducted annually by the American Society of Retina Specialists, 48% of its members who responded in 2004 had never tried small-gauge vitrectomy. By 2007, however, 80% of respondents used it for certain surgical cases (Mitra & Pollak, 2007).

3. Preoperative considerations

As our experience with this new technology has increased, the clinical application of small gauge vitrectomy (27-, 25-, 23-gauge) has expanded tremendously over the past 10 years. This growth has been fueled by the development of a wide array of small gauge instruments produced by multiple manufacturers for the various vitrectomy systems.

3.1 Indications

The surgical scope for small gauge instruments was initially limited to less challenging cases such as epiretinal membrane removal and macular hole repair. With increased surgical experience, improved endoillumination, and development of a wide array of instruments, the use of small gauge vitrectomy has expanded to include nearly all surgical cases. Although specific considerations need to be made, small gauge surgery, both 25- and 23-gauge, can now be performed for complex cases including rhegmatogenous retinal detachments (RD), posteriorly subluxed lens extraction, tractional RD, RD with giant retinal tears, and combined vitrectomy and scleral buckle procedure. Tractional retinal detachments from diabetic retinopathy or proliferative vitreoretinopathy are now commonly performed using small gauge vitrectomy, and even considered to be ideal for these surgeries (Charles, 2007).

Silicon oil injection can now be performed using both 25- and 23- gauge instruments, most commonly with 1000 centistokes silicone oil (Erakgun & Egrilmez, 2009). Certain cases, such as removal of intraocular foreign body (IOFB), traumatic retinal detachment, biopsy of uveal melanoma, and vitreous or choroidal biopsy for intraocular lymphoma, that were initially felt to be feasible only with 20-gauge instruments, have now been performed successfully using small gauge systems (Abi-Ayed et al, 2011; Elrich & Franzco, 2011; Fabian & Moisseiev, 2011; Kunikata et al., 2011; Yeh et al, 2010; Trikha et al., 2010). Initial concerns that small gauge vitrectomy may lead to diminished sensitivity of vitreous biopsy for intraocular lymphoma do not appear to be supported by experimental data (Trikha et al,

2010). Most recently a 23-gauge combined endoscope, laser and illuminator has been developed for both vitrectomy and endolaser cyclophotocoagulation.

Small gauge vitrectomy offers a major advantage in pediatric surgeries, where close proximity of intraocular structures and reduced space for sclerotomy placement make larger gauge instruments more challenging to use (Gonzales, 2006, 2009). It has been successfully used in pediatric cases involving retinopathy of prematurity, vitreous hemorrhage, rhegmatogenous retinal detachment, persistent fetal vasculature, cataract, dislocated lens, endophthalmitis, macular pucker, traumatic macular hole, familial exudative vitreoretinopathy, and retained lens fragment (Gonzales, 2009). Hybrid vitrectomy techniques utilize both 20-gauge and small gauge ports, and can be employed when specific small gauge instrumentation is insufficient or not available (Kongsap, 2010). This technique can also be utilized to decrease surgical time when instilling or removing 5,000 centistoke silicone oil. Currently, small gauge pars plana lensectomy is only effective on soft cataracts, while dense cataracts require at least one 20-gauge port, although 23-gauge phacofragmenters are currently being developed (Thompson, 2011).

The table below lists some of the many indications for small gauge vitrectomy in both adult and pediatric eyes.

Adult	Pediatric
ERM Peel	ROP
Macular Hole	Vitreous hemorrhage
Posteriorly Subluxed Lens	Cataract extraction
Tractional RD	Endophthalmitis
Silicone Oil Injection	ERM Peel
Vitreous Hemorrhage	Macular hole
Rhegmatogenous RD	FEVR
Uveal/ Vitreous Biopsy	Persistent fetal vasculature
IOFB Removal	Retained lens fragments
Endophthalmitis	

Table 1. Indications for small gauge vitrectomy in adult and pediatric eyes.

3.2 Previous ocular surgery

Eyes that have undergone, or might undergo, a glaucoma filtering surgery are excellent candidates for small gauge surgery (Recchia et al., 2010). The small incisions created by 25- and 23-gauge vitrectomy, reduces conjunctival trauma and allows for preservation of filtering blebs. Additionally, eyes that have recent corneal or scleral wounds from surgery or trauma can develop wound leakage during trocar insertion. Wounds should be inspected and sutured if necessary prior to creating new incisions.

4. Small gauge vitrectomy design

The development of small gauge instrumentation has been fueled by the quest for decreased ocular trauma, faster patient recovery, and shorter surgical time. These advantages have

come with a few drawbacks specific to the gauge and design of the vitrectomy system, and the surgical techniques utilized. With decreasing size, there has been tremendous focus not only on the design of the vitrector, but also on illumination, laser, and multifunction instruments.

With small vitrectomy instruments, scleral incision size has significantly been reduced. Table 2 lists the sizes of the incisions created using the available vitrectomy instruments. Prior to the use of small gauge instruments, PPV required conjunctival and scleral incisions, both of which needed suturing at the conclusion of the procedure. The use of small gauge vitrectomy instruments allows the surgeon to create a single, transconjunctival, scleral incision for access to the vitreous.

Gauge	Scleral Incision Size (mm)
19-G	1.1
20-G	0.9
23-G	0.60
25-G	0.50
27-G	0.40

Table 2. Scleral Incision Size Created by Various Gauge Vitrectomy Systems

4.1 Trocar cannula system

Sutureless, transconjunctival 25-gauge vitrectomy was the first widely used small gauge vitrectomy system. Initially developed by Bausch & Lomb (B&L Rochester, NY) it was quickly adopted by other manufactures. The basic surgical technique is similar to its 20-gauge precursor, with 3 scleral incisions made to allow for placement of infusion and instrument cannulas. A number of manufactures have now developed small gauge vitrectomy systems including Alcon (Alcon, Ft Worth, TX, USA), Synergetics Inc. (O'Fallon, MO, USA), and Dutch Ophthalmic, USA (Kingston, NH, USA).

The key to small gauge instrumentation is the use of a trocar cannula system, which allows for the simultaneous creation of a small-gauge sclerotomy and insertion of a flexible polyamide cannula. The conjunctival incisions are made while the trocar-cannula is passed in a single transconjunctival scleral incision for all vitrectomy ports. Prior to the trocar incision, the conjunctiva is displaced using a cotton tip applicator or forceps, to intentionally misalign the scleral and conjunctival openings. This allows the conjunctiva to cover the sclerotomy after the cannula is removed. The cannula remains in place during surgery and aligns both the conjunctival and scleral incisions, to allow for easy insertion and withdrawal of instruments. Care should be taken not to tear the conjunctiva during displacement, especially when using forceps. Although conjunctival displacement is intended to reduce the risk of contamination of the scleral wound after surgery, it has not demonstrated prevention of ocular surface fluid from entering the scleral wound in experimental studies (Singh, A. et al., 2008).

The trocar cannula system is composed of a microcannula that is mounted onto a sharp trocar. Since the original development, the trocar cannula system has been modified with improvements in the trocar needle design and sharpness, allowing for improved wound

construction and easier cannula placement. The cannula is composed of a polyamide tube mounted to a polymer cannula hub or collar. The cannula creates an entry port through the conjunctiva and sclera. The collar maintains the position of the cannula, and prevents it from sliding too far into the vitreous chamber. The collar also provides a platform to allow the surgeon to grasp the cannula, and some have an opening that is funnel-shaped to assist during instrument insertion.

Trocar cannula system includes plugs that can be fitted into the cannula collar to occlude the opening. The plug is designed with a tapered shaft that provides a tight fit into the cannula port. It is important not to force the plug too deep within the cannula to avoid difficulty during removal. During removal it is helpful to have a second instrument to stabilize the cannula hub during removal. This will help inadvertent withdrawal of the entire cannula if the plug is tightly fitted. Additionally, if there is forceful egress of fluid from an open cannula, lowering of the IOP will reduce the risk of projectile plug expulsion due to high outflow pressure from the port. The infusion is a metallic tube that is designed to fit into a cannula port. The cannula system has the added advantage of interchangeability of the instrument and infusion sites, which allows for improved access in certain cases. Valved cannulas have been introduced to obviate the need to cannula plugs when the port is not being utilized. This can reduce the risk of intraoperative hypotony, but also increases the possibility of accidental cannula removal when withdrawing an instrument due to increased friction from the cannula valves on the instrument.

4.2 Wound construction

In standard 20-gauge vitrectomy surgery, conjunctival incisions are made to expose the sclera in preparation for sclerotomy placement. A microvitoretinal blade (MVR) is used to make perpendicular incisions through the sclera, 3 to 4 mm posterior to the limbus. The infusion cannula is placed in the inferotemporal region, and sutured to the sclera to avoid accidental dislocation intraoperatively. Two additional sclerotomies are made near the 10 and 2 o'clock positions for instrument access to the vitreous cavity. Although 20-gauge cannulas are available and used by some, vitrectomy instruments in 20-gauge vitrectomy are most commonly passed directly through the scleral incisions without the use of a cannula system (Rizzo et al., 2009).

The most critical step in small gauge vitrectomy is the configuration and correct placement of the scleral incisions. The early descriptions of small gauge sclerotomies involved creating a perpendicular transconjunctival incision with conjunctival displacement (Fujii et al., 2002). This technique was modified to an oblique scleral incision after studies demonstrated better wound closure and reduced risk of hypotony (Hsu et al., 2008; Inoue et al., 2007; Taban et al., 2009). R.P. Singh et al. in a histopathologic study using rabbit eyes demonstrated increased leakage of intraocular dye in straight (perpendicular) incisions versus angled (oblique) incisions, in both 25- and 23-gauge vitrectomy systems (R.P. Singh et al., 2008). Similarly, Gupta et al., demonstrated decreased wound integrity in eyes that underwent 25-gauge PPV with perpendicular scleral incisions compared to beveled incision (Gupta et al., 2009). In this study, dye placed on the ocular surface of human cadaver eyes had more wound penetration in 25-gauge perpendicular incisions than in 25-gauge beveled incisions. Taban et al., utilizing both optical coherence tomography and india ink ingress, evaluated differences in wound integrity with both 25- and 23-gauge, straight and angled incisions on

cadaver eyes (Taban et al., 2008). This study found that angled incisions had better wound apposition under dynamic IOP than stright incisions. India ink applied to the surface after incisions were made fully penetrated through some straight incisions, but were not found in any of the angled wounds.

Shelved sclerotomy construction has been described in a one-step or two-step method. The one-step incision involves simultaneous entry of a sharp trocar with a mounted cannula. The trocar is removed and the cannula left in place for the remainder of the surgery. One-step oblique incisions can be made perpendicular or parallel to the limbus (Lopez-Guajardo et al., 2006, Shimada et al. 2006). Due to the orientation of scleral fibers in this region, scleral incisions made parallel to the limbus offers a theoretical benefit of displacing scleral fibers, rather than cutting them, as in incisions that are perpendicular to the limbus (Lopez-Guajardo et al., 2006). In addition, incisions that run parallel to the limbus are less likely to encroach the lens or retina.

Additional modifications to the one-step incisions have been made to improve wound architecture. A biplanar scleral incision involves changing the angle of entry during insertion of the trocar blade through the sclera. One variation includes initiating the scleral incision at a 30-degree angle tangential to the sclera, then repositioning to an angle that is perpendicular once the blade has partially entered the sclera. Alternatively, a more acute (5 degree) initial entry angle can be made with a more vertical angle upon completion of the scleral tunnel. Although no clinical trial we could find demonstrated a significant benefit of this biplanar scleral incision, it does offer the benefit of avoiding the peripheral retina after the trocar has entered the vitreous.

In the two-step method, the displaced conjunctiva is stabilized with a pressure plate instrument, while a shelved incision is created using a sharp angled blade (Eckardt, 2005). The blade is removed and a cannula is inserted along the same transconjunctival path using a blunt trocar. Advantages of the two-step method, including more consistent wound creation and improved stabilization of the eye with the pressure plate, are off set by the increased difficulty in spate placement of the cannula as well as increased overall time. Correct location for sclerotomy placement can be determined by using traditional calipers, or by using the fixed caliper that is now found on most small gauge vitrectomy systems. Trocar fixed calipers cause minimal conjunctival trauma, and allow the surgeon to quickly measure between 3 and 4 mm from the corneal limbus, eliminating the need for an additional instrument.

Due to the reduced caliber of small gauge vitrectomy instruments, flexion of the instruments during manipulation of the globe, poses a major disadvantage. For this reason, in small gauge vitrectomy, the location of the superior vitrectomy ports should be made as close as possible to the horizontal plane of the eye (Figure 1). This reduces the need to rotate the instruments significantly to access the peripheral and superior retina. By limiting the torsion placed on the globe, there is less distortion of the scleral wound, and reduced issues with tool flexion. The superonasal trocar entry should be placed in a location that would allow the least restriction by the bridge of the nose during surgery. The superotemporal trocar entry should be made near the horizontal plane of the eye, in the area corresponding to the lowest point of the supraorbital rim (Charles et al, 2007). The infusion is usually placed in the inferotemporal location, and can easily be transferred during surgery to either of the other cannulas.

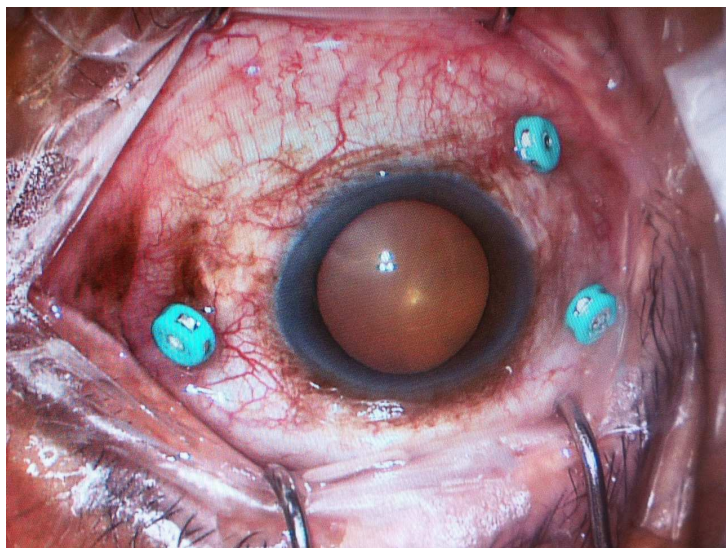


Fig. 1. Transconjunctival 25-Gauge vitrectomy ports placed in right eye. Note the trocars are valved to avoid fluid egress. The superior sclerotomy sites are seen at the bottom of the image. The upper right port in the image is the infusion site, and is located in the inferotemporal quadrant of the globe.

4.3 Fluidics

Vitreous has physical properties of both a solid and a liquid. It is 98% water, with the remaining material composed mostly of a matrix of collagen fibrils, large molecules of hyaluronic acid, non-collagenous proteins, glycoproteins, salts and sugars. Because of its dual liquid and solid physical properties, and attachment to intraocular structures, vitreous has to be excised as it is removed to reduce traction on the retina. This requirement necessitated the need for the development of the current vitrectomy instrument. Understanding of the flow of vitreous and liquid through the various vitrectomy systems has important clinical relevance.

The flow of a non-compressible fluid through a tube is governed by Poiseuille's equation. Based on this formula, the flow rate is directly proportional to the inner radius of the tube to the fourth power, and the pressure gradient on either end. Flow rate is inversely related to the length of the tube and the viscosity of the fluid. The clinical application of this principle to small gauge vitrectomy shows that the inner diameter of the small gauge vitrectomy systems will have the greatest impact on the flow of fluid, into and out of the eye. Studies, however, have shown that since the vitreous does not behave as liquid, other factors affecting flow, including vacuum pressure, cut rate and duty cycle of the vitrector are critical features governing flow rate in clinical settings (Hubschman et al 2008; Magalhaes et al. 2009). Fujii et al., in their introduction of a 25-gauge vitrectomy system reported a 40% greater flow rate with 25-gauge vitrectomy at 1500 cuts per minute (cpm) and 500 mmHg of vacuum, compared to 20-gauge vitrectomy at 750 cpm and 250 mmHg of vacuum (Fujii et al., 2002). They went on to report, however, that flow rates with 25-gauge (at 500 mmHg vacuum and 1500 cpm) was 2.3 times lower than 20-gauge vitrectomy at a high cut rate (250 mmHg vacuum and 1500 cpm).

The basic principle of the vitrector is to create a suction force into the port, allowing for vitreous to enter, and then cutting this segment of vitreous to relieve traction on the remaining vitreous body. The duty cycle in this process refers to the percentage of time the cutter port is open relative to each cutting cycle. Duty cycle varies depending on the type of vitrectomy drive mechanism utilized (Magalhaes et al., 2009). The three major types of drive mechanisms for vitrectomy handpieces are the guillotine electric, guillotine pneumatic, and the reciprocating rotary pneumatic. The electric drive system maintains a constant duty cycle regardless of cutting speed. The guillotine pneumatic drive system produces a high duty cycle (port is open longer than it is closed during each cycle) during slow cut rates, and a low duty cycle at high cut rates (port is closed longer than it is open). Finally, the reciprocating rotary pneumatic cutter also provides a constant duty cycle regardless of cut rate (Rizzo et al., 2009). In the guillotine pneumatic cutter, variation in duty cycle occurs because the speed at which the cutter closes is faster than the speed at which the cutter opens. The opening speed in this system is limited by relatively slower spring mechanism employed to place the cutter back into its open port position. During high cut rates, the inability of the spring drive opening to keep up with the pneumatically driven closure, increases the time the port is in the closed position, thereby decreasing the duty cycle. In the reciprocating pneumatic cutter, a duel line system is utilized, allowing for port closure and opening to be pneumatically driven at the same rates. The newest pneumatic vitrectomy systems employ this technology and allow the surgeon to vary duty cycle between 50% (the port is open and closed for the same duration in a cut cycle, similar to electric drive cutters), less than 50% (biased towards closed port), or more than 50% (biased towards open port) (Alcon Constellation® and Bausch & Lomb Stellaris PC®). Since the optimal duty cycle varies depending on the physical properties of the material being removed, some believe pneumatic vitreous cutters are more versatile during vitreo-retinal surgery (Charles et al, 2007).

Cut rates of all vitrectomy systems have increased since the original design. This movement has been propelled by the belief that higher cut rates will decrease vitreous traction during all aspects of vitrectomy. High cut rates have traditionally come at the cost of reduced flow and removal of vitreous. This effect of cut rate on flow was seen with the older generation pneumatic cutters in the leading vitrectomy system (Accurus®), but was not seen in electric vitrectomy cutters. The latest vitrectomy systems are capable of cut rates up to 5000 cpm in 20-, 23-, and 25-gauge formats (Constellation® and Stellaris PC®). These vitrectomy systems both employ duel line pneumatic cutters that allow for 50% duty cycle at the highest cut rates.

4.4 Infusion

Small gauge vitrectomy systems utilize a cannula-based infusion line that has a precise sliding fit within the microcannula. The fit is tight enough to provide enough resistance to prevent ejection under high infusion pressures. Balanced salt solution (BSS) flow rate through the infusion cannula is most influenced by the diameter of the lumen of the tube and microcannula (Rizzo et al, 2009).

4.5 Vitreous cutter design

The general design of the vitreous cutters in microrincisional surgery is the same as 20-gauge vitreous cutters. Electric vitrectors are much larger in overall size than pneumatic cutters,

regardless of the gauge used. The major differences between newly designed small gauge vitrectomy probes and traditional 20-gauge vitrectomy probes, are lumen diameter, stiffness of the shaft and distance of the vitrectomy port from end of the probe.

Stiffness of the vitrectomy probe becomes clinically relevant in surgery that requires significant eye rotation to reach peripheral retina. Hubschman et al., studied the stiffness of 25-, 23-, and 20-gauge vitrectomy probes from various developers (Hubschman et al., 2008). Stiffness of the shaft of each vitrectomy probe was determined by measuring the displacement of the tip of the probe under a constant force. The study found that differences in probe stiffness was explained by differences in metal properties, thickness in shaft wall (difference between external and internal diameter), and probe length.

The external and internal diameters of the various probes were also measured. There was very little variation in the external diameter among the four 25-gauge probes (0.5mm) and two 23-gauge probes (0.5mm) (Hubschman et al, 2008). This is to be expected, since the gauge of vitrectomy instruments is classified based on the external diameter. Interestingly, the internal diameter varied significantly among 25-gauge (range 227 um to 292 um) and 23-gauge (355 um to 318 um) vitrectomy probes.

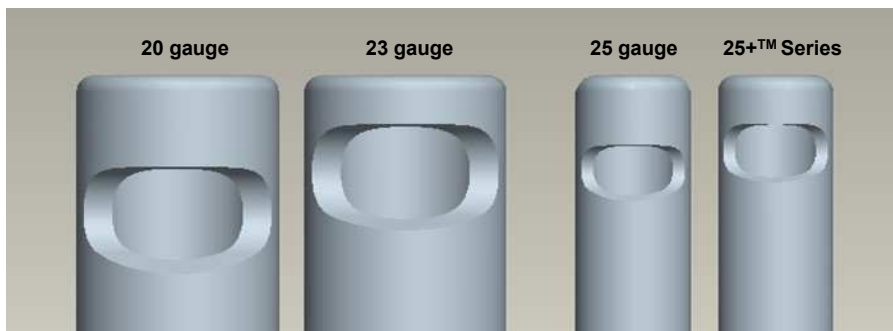


Fig. 2. Vitrectomy probes of various gauge systems (Alcon, Ft Worth, TX, USA). Note the port opening size and location. The port opening location is closer to the the end of the probe in both the 23-gauge and 25-gauge systems compared to the conventional 20-gauge system.

Another major advantage in design of small gauge vitrectomy has been the displacement of the opening closer to the end of the vitrectomy probe. This shift has been made possible by increased vitrectomy cut rates and improvements in fluids of the vitrectomy systems, both of which have made it safer to operate closer to the retina. Although delamination and segmentation using intraocular scissors is still necessary in many cases, positioning of the port closer to the probe tip has made it possible to dissect epiretinal membranes using the vitrector alone. This has proven to be of great value removing preretinal membranes in patients with proliferative diabetic retinopathy.

4.6 Endoillumination

Smaller gauge endoillumination probes initially produced significantly reduced light output compared to the 20-gauge probes. The development of higher-output light sources and

wide-angle light probes has eliminated inadequate illumination in small gauge vitrectomy. Although, brighter light can be achieved with new xenon and mercury vapor sources, the risk of phototoxicity should be considered, especially during macular surgery. Illuminated infusion cannulas and chandelier lights are also available and allow for bimanual surgery. Improved quality of illuminated laser probes enables more efficient delivery of laser, along with the option for surgeon-performed depressed exam and peripheral laser.

A Chandelier light is now available in 25- and 27-gauge light probes, and is inserted in the pars plana to provide a continuous, hands-free illumination of the vitreous cavity. This light probe is usually placed inferiorly, although it can be inserted elsewhere depending on surgeon's need and preference. Directing the chandelier probe more posteriorly than the usual entry angle reduces glare and allows for diffuse endoillumination of the posterior chamber (Charles et al, 2007). Although the use of this device allows for true bimanual surgery, it has limited utility compared conventional light probes.

4.7 Cannula withdrawal and wound closure

At the completion of the surgery, the cannulas are removed using forceps, with simultaneous application of pressure on the scleral wound using a cotton tip applicator. If a valved cannula is not being used, instrument ports should be closed with a plug at the time of the cannula removal. This allows for inspection of the wound for leakage, and suturing if necessary. Just prior to removal of a cannula, the infusion is clamped or the pressure is lowered to 5 mmHg. With pressure applied to the scleral wound using a cotton tip applicator, the infusion is activated to a pressure of 25 to 30 mmHg. With this technique, the internal pressure from the infusion and the external pressure from the cotton tip forces the shelved incision to close. The conjunctiva is gently pushed back to its original position to cover the sclerotomy. The infusion is removed last, as with standard vitrectomy. If wound leakage is noted, a dissolvable suture is placed through the conjunctiva and sclera to close the sclerotomy. In some situations, chemosis or hemorrhage reduces the ability to visualize the scleral wound, and a small conjunctival incision is necessary for suture placement. If the eye is hypotonus after removal of all cannulas, then BSS or sterile air is injected to achieve optimal IOP. Some surgeons perform a partial air-fluid exchange at the completion of surgery to reduce risk of hypotony. The increased surface tension of air versus liquid is felt to reduce the wound leakage from the sclerotomy sites.

5. Surgical technique

The general procedure for small gauge vitrectomy is the same as with traditional 20-gauge vitrectomy. Standard sterile procedure using povidone-iodine (Betadine 5%) is utilized to prepare the eye, and instilled on the ocular surface. Sterile drapes are used per standard protocol. In small gauge vitrectomy, the use of an adjustable lid speculum is advantageous over spring retractors. This mostly relates to the ability to reduce lid retraction to provide increased conjunctival laxity for sufficient displacement during trocar insertion.

Disposable trocars for small gauge surgery come pre-loaded with cannulas. Care should be taken by the assistant to avoid inadvertent removal and loss of the cannula during handling. Measurements are made for sclerotomy location, and can be done using fixed calipers on the back of the trocar, if present. Most surgeons place cannulas 3.0 mm to 3.5 mm posterior to

the limbus in aphakic or pseudophakic eyes, and 3.5 to 4.0 mm in phakic eyes. A cotton-tipped swab is best for displacing the conjunctiva since it is least traumatic, and less likely to create a tear that would require suturing. The scleral mark created from the caliper should be visible through the displaced conjunctiva. The trocar is inserted in an oblique angle, parallel to the limbus, and oriented more vertically prior to entering the vitreous. The 23-gauge cannulas should be inserted at a more acute angle (5 degrees) than 25- or 27-gauge systems. This allows for a longer scleral tunnel and better wound closure. With this method a two-step incision reduces the risk of penetration into peripheral pars plana after entry into the vitreous.

The infusion port is placed first, usually in the inferotemporal region. Sterile drape or tape is used to secure the infusion line and direct it to the mid-vitreous. Correct positioning of the cannula in the vitreous is verified prior to infusion activation. The superior cannulas are then inserted near the 10 and 2 o'clock positions. As mentioned earlier, with smaller gauge systems, positioning of the superior cannulas closer to the horizontal plane of the eye improves access to the superior peripheral retina. The instruments can then be inserted for vitrectomy. When removing instruments, the cannula should be observed for inadvertent removal. If the cannula appears loose, then forceps should be utilized during instrument removal. If the cannula is accidentally removed, it can be reloaded onto the trocar and inserted into the same wound if possible. Otherwise, a new transconjunctival incision is made in a new location.

5.1 Macular surgery

Macular surgery is an ideal indication for small gauge vitrectomy, as it requires less manipulation of the instruments and less need for thorough dissection of the peripheral retina. Indications for this surgery include macular pucker, macular hole, vitreomacular traction syndrome, macular edema, subhyaloid or submacular hemorrhage. As with most vitrectomy surgeries, a core vitrectomy is first performed. This is usually followed by induction of a posterior vitreous detachment (PVD), if not already present. This step highlights a disadvantage in some of the small gauge vitrectomy systems, where substantially low flow rates create difficulty in detaching the vitreous from the optic nerve. The vitreous cutter or a soft tip cannula can be utilized, and is set to active extrusion between 400 and 500 mmHg. The infusion rate should be increased if hypotony is noted during active suction. The soft-tip cannula or vitrector is held at the disc margin and aspiration is applied. The cutter should be turned off if using the vitrector. Engagement of adherent vitreous is seen as a slight elevation of the disc margin due to vitreous traction. Anterior movement of the aspiration instrument is often sufficient to detach the vitreous from the nerve, but in some cases, tangential traction is also required to achieve this result. Vitreous staining can be done using triamcinolone and can identify any residual adherent vitreous. If the posterior hyaloid is strongly adherent, a bent MVR blade or a long 25-gauge needle can be used to separate the posterior hyaloid around the optic nerve. This is best performed using a contact lens for improved visualization. Once separated from the optic nerve, the vitrector or soft-tip can be used to elevate the hyaloid over the macula. Extra care should be employed in diabetic patients to avoid trauma to adherent blood vessels.

If epiretinal membrane (ERM) or internal limiting membrane (ILM) peeling is necessary a macular contact lens is utilized. Some surgeons prefer to create a membrane edge using

micro-pick, bent MVR blade or needle, or a diamond dusted membrane scraper. Once an edge has been created, membrane forceps can be used to carefully strip the tissue from the retinal surface. For peeling of the ERM or ILM, staining of the retina can be performed using indocyanine green (ICG), trypan blue, or triamcinolone. Use of these agents can also uncover incomplete vitreous separation from the posterior pole. Additionally, use of stains can help ensure complete peeling of the ILM and ERM of the central macular region, and possibly reduce the risk of reoperation. This benefit must be weighed against the potential risk of ocular toxicity that has been suspected with the use of some of these dyes (Rodrigues, EB et al., 2007).

Removal of membranes from the retinal surface using 25-gauge instruments can occasionally result in paradoxical movement of the tip of the forceps. This occurs because of flexion forces near the proximal end of the forceps create a reverse movement of the distal end of the forceps, in attempted rotation of the eye. If this occurs during membrane peeling, repositioning of the forceps and engaging a different area of the membrane to avoid tension on the globe will eliminate the problem. The increased stiffness of 23-gauge and newer 25-gauge instruments has nearly eliminated this effect.

Treatment for submacular hemorrhage can be performed by injection of subretinal tissue plasminogen activator (TPA). This technique can be performed with the use of any of the small gauge vitrectomy systems. A subretinal cannula, such as a 39-gauge submacular cannula is connected to a 3 ml syringe via extension tubing. TPA is used off label at a concentration of 12 ug/ 0.1 ml. Standard vitrectomy with PVD induction is performed. The subretinal cannula is then inserted directly through the retina without the need for a retinotomy. Injection using this technique should be performed over an area of subretinal hemorrhage, so that displacement of the subretinal hemorrhage can provide a visual clue that would indicate entry through the retina. Sufficient TPA is injected to create retinal elevation in the macula. Some surgeons use perfluorocarbon liquid to displace the liquefied hemorrhage away from the central macula, but this is not required. Laser photocoagulation is not required to seal the entry site of the submacular cannula. A peripheral retinal exam is performed as with all vitrectomy surgery, followed by air-fluid exchange and gas instillation. The choice of gas in this setting is surgeon dependent, but a short acting gas is sufficient to allow for displacement of subretinal hemorrhage. The patient is instructed to remain upright postoperatively for up to 1 week to allow for displacement of the hemorrhage.

5.2 Diabetic retinopathy

Surgical indications for diabetic retinopathy include non-clearing vitreous hemorrhage (VH), tractional retinal detachment (TRD), refractory diabetic macular edema, premacular subhyaloid hemorrhage, and ghost-cell glaucoma. With the expansion of small gauge surgical tools, 25- and 23- gauge vitrectomy cannot only be utilized for nearly all cases, but also offers a few additional advantages.

The surgical approach to performing ERM or ILM peeling, and relieving vitreomacular traction in diabetic patients are the same as in 20-gauge procedures. Special considerations for performing PVD and membrane peeling using small gauge systems have been discussed earlier. For treatment of VH and TRD, the main goals are to clear the media and relieve

macular traction. Eyes with a complete PVD preoperative are less likely to need vitrectomy, due to the lack of hyaloidal traction on the retina. Non-clearing vitreous hemorrhages are easily cleared with 23- and 25-gauge systems, and are more recently being performed with 27-gauge vitrectomy. The initial limiting factor of reduced flow and increased vitrectomy time with small gauge vitrectors has become less important with improvement in system fluidics. Endolaser probes are available in a variety of styles, including fixed curved and extendable curved, which allow for excellent access to peripheral retina without the need for significant rotation of the eye.

Diabetic tractional retinal detachments are treated with three basic surgical approaches. After performing a core vitrectomy and relieving anterior-posterior vitreous traction where possible, dissection of the posterior hyaloid from retinal adhesions is performed using the following techniques: segmentation, delamination, or en bloc separation. Segmentation involves severing vitreous adhesions between focal points of retinal attachments, leaving isolated segments of fibrovascular tissue adherent to the retina, without vitreo-retinal traction. Delamination, in contrast, involves separation of all vitreo-retinal attachments by dissecting parallel to the plane of the retina, with no residual fibrovascular tissue on the retinal surface. En bloc dissection involves separating the vitreous body and all adherent fibrovascular membranes as a single unit (Charles et al., 2007; Rizzo et al., 2009).

The size of the small gauge vitreous cutters and the more distal location of the vitrectomy port offer an advantage when performing dissection of fibrovascular tissue near the retina. The vitreous cutter can be used as a scissor to cut fibrous tissue with little traction on the retina. This reduces the need and frequency of repeatedly inserting vertical or horizontal scissors, although these are available in a variety of small gauge options. The added stiffness of 25 and 23-gauge instruments, along with the options for small gauge silicone oil instillation leaves very few diabetic vitrectomies that require large gauge instruments.

Ghost-cell glaucoma represents a complication of dense, chronic vitreous hemorrhage, with migration of degenerated red blood cells into the anterior chamber, and blockage of the trabecular meshwork with red blood cell debris or macrophages. Vitrectomy is performed in the setting of uncontrolled IOP, despite medical treatment. Small gauge vitrectomy systems allow for easy access of the vitrector, or even the infusion, into the anterior chamber through a paracentesis.

5.3 Rhegmatogenous retinal detachment

For uncomplicated rhegmatogenous RD, pars plana vitrectomy has become more widely used as a primary treatment technique, especially for pseudophakic and aphakic eyes. Benefits for vitrectomy over scleral buckling include controlled drainage of subretinal fluid, ability to remove vitreous opacities, identification of small breaks, minimal or no effect on refractive error. Vitrectomy, especially small gauge systems, causes less trauma to conjunctiva and sclera, avoids muscle manipulation, allows control of intraoperative pressure, and causes less patient discomfort after surgery, although this has not been proven. The increased incidence of cataract formation with vitrectomy is well known, and should be considered when selecting the surgical option. The risk for increased proliferative vitreoretinopathy (PVR) with vitrectomy compared to scleral buckling has not been proven, but is a debated issue.

Techniques for repair of rhegmatogenous retinal detachments using small gauge vitrectomy are similar to those using 20-gauge systems. Infusion pressures and aspiration for 25-gauge are set higher than those for 20-gauge vitrectomy, usually in the range of 35 to 45 mmHg for infusion, and between 600 mmHg for aspiration during vitrectomy. Superior ports should be placed close to the horizontal meridian to allow for increased access to the superior peripheral retina. A chandelier light infusion can be used but is usually not necessary. A variety of techniques are available to repair the retinal detachment depending on surgeon preference. A lighted laser allows the surgeon to perform scleral depression and simultaneously apply laser. Gas is most commonly used as a tamponade agent. For gas exchange, typically the surgeon removes one superior cannula and instills the gas mixture through the infusion cannula, although other techniques are also available. When using small gauge surgery, it is important to save some of the gas mixture until all cannulas are removed and inspected for leaks. If a sclerotomy demonstrates leakage and needs to be sutured, then the appropriate gas mixture can be injected upon completion to attain optimal IOP.

Silicone oil can now be injected and extracted using an automated system with both 23- and 25-gauge ports. Injecting high viscosity silicone oil (5000 cs) is very time consuming with this approach and does not offer any proven benefits over lower viscosity oil (1000 cs). Oil injection is performed in the same fashion as in 20-gauge vitrectomy, using very low infusion pressures. In combined scleral buckle and vitrectomy procedures, many surgeons use standard 20-gauge vitrectomy since the conjunctival incisions have to be made. Using a small gauge system with combined scleral buckle cases, however, does offer some benefits. For this procedure, a 360-degree conjunctival peritomy is made with isolation of the recti muscles using 2-0 silk ties. All buckle components can then be placed prior to vitrectomy. If the preference is to tie scleral sutures after vitrectomy, the infusion cannula can be temporarily relocated to a superior port to allow for better access to the inferotemporal quadrant. Scleral incisions using the trocar can still be made in a shelved fashion, and be left sutureless if no leak is seen.

5.4 Pars plana lensectomy

Small gauge vitrectomy is a viable alternative to the standard 20-gauge vitrectomy with phacofragmentation for retained lens fragments after complicated cataract surgery. In 2008, Kiss and Vavvas reported successful use of 25-gauge vitrectomy for the removal of retained crystalline lens (Kiss & Vavvas, 2008). In this study, they found that the 25-gauge vitreous cutter allowed for removal of softer lens material, however, cases involving dense nuclear fragments required sclerotomy enlargement and use of the 20-gauge phacofragmatome (Kiss & Vavvas, 2008). Similarly, Laurence Ho et al. also reported successful outcomes using 25-gauge vitrectomy to remove retained lens fragments (Ho, 2010). Removal of the vitreous surrounding the lens fragment is performed from anterior to posterior. After a complete vitrectomy with removal of all vitreous traction on the lens, the cutter can be set to a reduced speed, as low as 600 cpm, to remove lens material. The light pipe can be used to break up large lens fragments at the vitrectomy probe. The final visual outcomes for small gauge lensectomy have been reported to be similar to those obtained using the 20-gauge vitrectomy system. Incidence of postoperative complications after 25-gauge vitrectomy for retained lens fragments including glaucoma, cystoid macular edema and retinal detachment, was similar to that seen with 20-gauge instrumentation (Ho, 2010).

5.5 Pediatric surgery

Small gauge vitrectomy has been utilized for a wide variety of vitreoretinal disorders in the pediatric population. A major concern for the use of this technology for patients in this age group is the risk of hypotony and its associated complications. Children are more likely to rub their eyes and thus may cause wound leakage in the immediate postoperative period. Hypotony in children with vasoproliferative disorders could result in bleeding from sensitive vascular tissue. Sclerotomies in young children are made in the pars plicata, just posterior to the limbus, so sufficient conjunctival displacement of the sclerotomy incisions is difficult. To improve safety, some surgeons advocate suturing of both sclera and conjunctiva in younger children undergoing small gauge vitrectomy (Gonzales et al, 2006). Potential advantages that have been suggested with the use of small gauge vitrectomy in this subset of patients include increased accessibility to smaller spaces within the eye, such as between the lens and ridges in patients with retinopathy of prematurity (ROP), or between tight retinal folds in cases of tractional RD (Gonzales et al, 2009). Additionally, due to the small size of the eye and immature pars plana, small gauge vitrectomy allows for the use of 3 ports in some pediatric eyes that would otherwise have room for only two, 20-gauge ports.

Gonzales et al., reported successful outcomes for small gauge vitrectomy in pediatric eyes involving tractional RD secondary to retinopathy of prematurity (ROP), vitreous hemorrhage, rhegmatogenous RD, familial exudative vitreoretinopathy (FEVR), persistent fetal vasculature, cataract, dislocated lens, macular pucker, endophthalmitis, exudative RD, traumatic macular hole, retained lens material and aqueous misdirection (Gonzales et al., 2009). In their report, however, the authors cautioned that 25-gauge vitrectomy may not be the best approach in all pediatric surgery. It is possible that some limitations experienced with 25-gauge instruments, specifically, instrument stiffness, could be overcome with 23-gauge systems.

5.5.1 Retinopathy of prematurity

Previously, retinal detachment due to ROP was repaired with scleral buckle, using PPV only when the sclera buckle failed. More recently however, PPV has been used as the primary surgical approach, thus allowing for direct removal of vitreous traction, decreased compression of the anterior ocular structures and less surgically induced myopia. Prior to the popularization of small gauge vitrectomy, 20-gauge vitrectomy was used for RD repair in these patients. In 2006, Gonzales et al., described the three-port, pars plicata vitrectomy technique for RD repair (Gonzales et al., 2006). Conjunctival dissection is performed followed by creation of sclerotomies 0.5 mm to 1.0 mm posterior to the limbus, in the pars plicata. The infusion line is placed inferotemporally, unless this is the site of the tractional RD. In that event, the infusion should be placed away from the RD. An MVR blade is used to make the sclerotomies in the superotemporal and superonasal quadrants; trocar cannula system is not used for this technique. Lens sparing vitrectomies are employed unless there is significant retinal-lental touch or lens opacities obscuring view to the posterior pole. Upon completion of the surgery, the conjunctival and scleral wounds are sutured. This technique is best utilized in cases where views to the posterior are clear, particularly when there are no anterior tractional retinal folds in close approximation to the lens or extensive anterior fibrosis. Hemorrhage, presence of plus disease, and neovascularization have been associated with poor surgical outcomes in repair of retinal detachment secondary to ROP (Gonzales et al., 2006).

6. Advantages of small gauge vitrectomy

Numerous advantages have been proposed for small gauge vitrectomy including decreased ocular trauma and inflammation, reduced conjunctival scarring, shorter operative time, increased patient comfort, and faster visual recovery.

6.1 Decreased ocular trauma

The reduced trauma from smaller conjunctival and scleral incisions made in 25-, 23-, and 27-gauge surgeries has the theoretical advantages of reducing conjunctival scarring. This is of major importance in patients with previous or planned glaucoma surgery. In our experience it also limits irregular scar formation and conjunctival disfigurement.

6.2 Reduced surgical time

Fujii et al., in their initial report on 25-gauge vitrectomy, reported shorter operative times with sutureless vitrectomy compared to 20-gauge. Although they found slightly longer vitrectomy times due to reduced flow with the 25-gauge system, this was minimal in comparison to the time saved during opening and closing of the surgical wounds (Fujii et al., 2002). Reduced surgical times with small gauge sutureless vitrectomy has also been reported by others (Rizzo et al., 2006; Kadosono et al., 2006). Some studies have shown, however, that the time saved in managing the incisions, was lost because of longer duration of vitrectomy, resulting in no significant difference in surgical time (Kellner et al., 2007; Wimpissingwer et al., 2008, as cited in Thompson, 2011). Although reduced time managing the surgical wound as been attributed to the reduced time for surgery, other factors including less vitreous removal and easier case selection also favor this finding.

6.3 Patient comfort and recovery

One of the major advantages of small gauge surgery is reduced postoperative pain (Mentens et al., 2009). Small incision, as well as the lack of sclera and conjunctival sutures, are likely the major factors contributing to this finding. Additionally, visual recovery has been shown to be faster with small gauge vitrectomy, likely due to the lack of suture induced astigmatism found in 20-gauge vitrectomy (Hass et al., 2010). Patients in our practice rarely require narcotic medications for pain control following small gauge surgery, which were needed routinely following 20-gauge vitrectomy.

7. Complications of small gauge vitrectomy

7.1 Intraoperative

A number of intraoperative complications can occur with the use of small gauge vitrectomy systems. Most of these are related to the issue of IOP control, but also include suprachoroidal hemorrhage, retinal tears, and retinal toxicity from subconjunctival medications.

7.1.1 Hypotony

There is an increased risk of hypotony in small gauge PPV during the placement of the trocars. The force required to insert the trocar cannula complex is substantially greater than

that required to insert the 20-gauge MVR blade. This additional force is necessary because the trocars in small gauge surgery are not as sharp as 20-gauge MVR blades, and because the cannula is intended to be forced through the slightly smaller trocar incision. The tight fit of the cannula in the scleral incision creates resistance to dislocation of the cannula during removal of instruments. Additionally, placement of trocars requires the application of a compressive force to the globe to penetrate the sclera at an oblique angle (Wu et al., 2011). This force on the globe during insertion of the trocars has been shown to increase the IOP to as high as 63.7 mmHg (Dalma-Weiszhausz et al., 2008). The redesign of some trocar needles has partially reduced this problem. In patients with recent corneal or scleral wounds, such as those with recent cataract surgery, penetrating keratoplasty, or repair of a ruptured globe, the initial trocar insertion can cause wound leak with resultant hypotony and its associated risks (Wong et al., 2010). Careful inspection of all ocular wounds should be made prior to placement of new surgical incisions. All suspicious wounds should be sutured prior to placement of vitrectomy ports.

Eyes that have undergone previous vitrectomy are also more likely to have hypotony during trochar placement. This is most evident during placement of the superior cannulas, following successful placement of the infusion cannula. As the superior cannula is being inserted, IOP elevation causes fluid from the vitreous cavity to be displaced into the infusion cannula, with resultant deformation of the globe. In non-vitrectomized eye, fluid egress through the infusion is restricted by vitreous plugging of the infusion port, thereby providing more resistance to compression. This issue can be addressed by temporarily increasing infusion pressure at the time of trochar insertion for the second and third cannulas. Similarly, some surgeons do not always place a plug in the instrument cannula when inserting the final trochar, relying on the vitreous to temporarily plug the open cannula. Although this does not usually create an issue, eyes that have significantly liquefied vitreous or prior vitrectomy, have an increased risk of hypotony because intraocular fluid can easily escape from the open cannula.

7.1.2 Cannula related complications

The infusion is the source of a few complications during small gauge vitrectomy. First, the infusion cannula is not sutured to the sclera, therefore, it can inadvertently be dislocated or pulled out. This is most likely to occur during scleral depression. Sudden loss of infusion and resultant hypotony during surgery has its obvious complications, including hemorrhage, choroidal detachment and retinal trauma from intraocular instruments. The best immediate solution is to replace the infusion into any cannula to pressurize the globe. The dislocated cannula can then be placed over a trocar and reinserted.

The use of cannulas for instrumentation also has a direct effect on the infusion. In small gauge vitrectomy, high velocity flow from the infusion can occur if there is rapid removal of fluid from the eye through an open cannula during exchange of instruments. The high infusion pressure can cause direct mechanical trauma to the retina, increased dehydration if air-fluid exchange has already been performed, or high flow infusion into a macular hole with resultant injury. Valved cannulas have recently been released to address this issue. Unusual complications with small gauge instruments have also been reported including breakage and intraocular dislocation of a segment of a cannula tip, as well as intraocular breakage of the vitrectomy tip (Chen C. et al., 2008; Inoue et al., 2004).

7.2 Postoperative complications

7.2.1 Hypotony

Since the initial introduction of small gauge, sutureless vitrectomy, there has been a great deal of concern for postoperative hypotony. Several papers have reported the incidence of hypotony after 25-gauge vitrectomy, ranging from 3.8% to 16% (Chen E., 2007; Byeon, 2006). The wide range of incidence has mostly been attributed to variations in the definition of hypotony, incision technique, instrument design, variation in surgical manipulation of instruments, and surgical techniques (Chen D. et al., 2010). Hypotony after sutureless vitrectomy is usually transient, resolving within the first week of surgery as the sclerotomies heal sufficiently (Bamonte et al., 2011).

Bamonte et al. reported on the incidence of postoperative hypotony, defined as IOP of 5 mmHg or less, in their series of 25-gauge sutureless vitrectomy. They found that lens status, choice of tamponade, use of intravitreal triamcinolone, and reoperations to be independent risk factors for postoperative hypotony. Lens status has been shown to be a risk factor for postoperative hypotony with small gauge vitrectomy (Bamonte et al., 2011). Phakic eyes that did not undergo combined cataract extraction had a lower incidence of postoperative hypotony. This might be explained by the limited peripheral vitrectomy that is performed in these eyes to avoid lens contact.

Eyes undergoing primary small gauge vitrectomy have been shown to have a lower rate of postoperative hypotony compared to eye with previous vitrectomy (Bamonte et al., 2011; Shimada et al., 2006). It has been suggested that this finding could be a result of alterations in the elasticity and regenerative capacity of scleral tissue, leaving wounds in this tissue more prone to leakage. Additionally, revitrectomized eyes have more thorough vitreous removal, resulting in less vitreous plugging of the scleral wound. Vitreous base dissection has been shown to increase the rate of postoperative hypotony in 23-gauge surgery (Woo, et al., 2009).

Air or gas filled eyes have been shown to reduce the risk of hypotony (Bamonte et al., 2007; Shimada et al., 2006). It is felt that increased surface tension of air compared to BSS results in less leakage at the sclerotomy sites. This has led some surgeons to advocate a partial air-fluid exchange in eyes that undergo sutureless surgery, and that do not have a gas tamponade. The benefits of this technique on reducing the rate of postoperative hypotony has been demonstrated for both 25- and 23-gauge vitrectomy (Parolini et al., 2010; Shimada et al. 2006).

7.2.2 Endophthalmitis

The rate of endophthalmitis with small gauge sutureless vitrectomy has been a concern. A very large retrospective study found a 12-fold increased risk of 25-gauge vitrectomy compared to 20-gauge vitrectomy (Kunimoto & Kaiser, 2007). In this study, Kunimoto and Kaiser reported an incidence of 0.23% (7/3,103 eyes) for 25-gauge and 0.018% (1/5,498 eyes) for 20-gauge vitrectomy. Limitations in the study included the retrospective nature and the use of triamcinolone in some cases of apparent endophthalmitis. Two other large studies have demonstrated a higher incidence with small gauge vitrectomy, but the differences were not significant (Scott et al., 2011; Chen, J. et al., 2009). Shimada et al., modified several aspects of 25-gauge vitrectomy, including creating shelved incisions, and found no difference in endophthalmitis rate compared to 20-gauge vitrectomy (Shimada et al., 2008).

The proposed mechanism for a possible higher risk of endophthalmitis is migration of bacteria from the ocular surface through the conjunctival and scleral wounds. Passage of India ink dye from the ocular surface into the scleral incision was demonstrated in rabbit eyes after 25- and 23-gauge incisions (Singh, 2008). The possible protective effect of angled incisions was demonstrated in this histopathologic study, and supported with clinical reports that had no endophthalmitis with shelved 25- and 23-gauge incisions (Gupta et al., 2008; Ibarra, 2005). It is possible that risks can be reduced with better wound construction using shelved incisions, conjunctival displacement, and prophylactic antibiotics.

7.2.3 Retinal detachment

It was hoped that the introduction of cannulas would reduce the incidence of retinal detachment due to less traction on the vitreous base during entry and removal of instruments. No large prospective trial has been performed to study this complication, but a very large retrospective study of 2,432 vitrectomies found no significant difference in the rates of retinal detachment between small gauge vitrectomy (23- and 25-gauge) and 20-gauge vitrectomy, or between 23- and 25-gauge vitrectomy (Rizzo et al., 2010). Reported rates of postoperative retinal detachment following 25-gauge vitrectomy have been similar to those reported for 20-gauge vitrectomy (Byeon, 2006; Ibarra, 2005). Table 3 summarizes the complications associated with small gauge vitrectomy.

Intraoperative	Postoperative
Hypotony	Hypotony
Intraocular Dislocation of Cannula	Endophthalmitis
Intrument Breakage	Retinal Detachment

Table 3. Complications of small gauge vitrectomy

8. Conclusion

Small gauge vitrectomy offers a number of advantages compared to the standard 20-gauge vitrectomy. Improvements in vitrector design and fluidics, as well as the development of a wide array of small gauge instruments, lasers, and illumination devices has significantly broadened the scope for small gauge vitrectomy surgery. As continued developments are made, 20-gauge vitrectomy may play a decreasing role in vitreoretinal surgery.

9. References

- Abi-Ayed, N., Grange, J., Salle, M., & Kodjikian, L. (May 2011). Transretinal uveal melanoma biopsy with 25-gauge vitrectomy system. *Acta Ophthalmology*, 1755-3768 [E pub ahead of print]
- Augustin, AJ. (2009) Historical overview of microincision surgery, In: *Vitreoretinal surgery progress III*, Rizzo S., Patelli, F. & Chow, DR, pp. (1-8) Springer, 1612-3212, Heidelberg, Germany
- Brazitikos, PD. (2000). The expanding role of primary pars plana vitrectomy in the treatment of rhegmatogenous noncomplicated retinal detachment. *Semin Ophthalmol*, Vol. 15, No. 2, (June 2000), pp. (65-77), 0882-0538

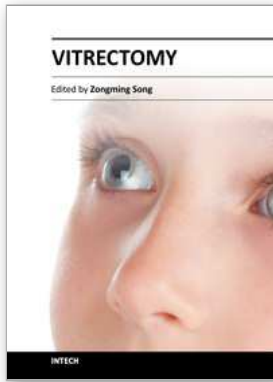- Bamonte, G., Mura, M., & Tan, S. (2011). Hypotony after 25-gauge vitrectomy. *Am J Ophthalmol*, Vol. 151, (January 2011), pp. (156-160), 0002-9394
- Byeon, SH, Chu, YK, Lee, SC, Koh, HJ, Kim, SS, & Kwon, OW. (2006). Problems associated with the 25-gauge transconjunctival vitrectomy system during and after surgery. *Ophthalmologica*, Vol. 220, No. 4, (2006), pp. (259-265), 0030-3755
- Charles, S., Calzada, J., Wood, B. (2007). *Vitreous Microsurgery* (Fourth edition), Lippincott Williams & Wilkins, 0-7817-6443-2, Philadelphia, PA.
- Chen, CJ., Satofuka, S., Inoue, M., Ishida, S., Shinoda, K., & Tsubota, K. (2008). Suprachoroidal hemorrhage caused by breakage of a 25-gauge cannula. *Ophthalmic Surg Lasers Imaging*, Vol. 39, No. 4, (July 2008), pp. (323-324), 1542-8877
- Chen, D., Lian, Y., Cui, L., Lu, F., Ke, Z., & Song, Z. Sutureless vitrectomy incision architecture in the immediate postoperative period evaluated in vivo using optical coherence tomography. *Ophthalmology*, Vol. 117, No. 10, (Oct 2010), pp. (2003-2009), 0161-6420
- Chen, E. (2007). 25-gauge transconjunctival sutureless vitrectomy. *Curr Opin Ophthalmol*, Vol. 18, No. 3, (May 2007), pp (188-193), 1040-8738
- Chen, JK, Khurana, RN, Nguyen, QD, & Do, DV. (2009). The incidence of endophthalmitis following transconjunctival sutureless 25- vs 20-gauge vitrectomy. *Eye (Lond)*, Vol. 23, No. 4, (Apr 2009), pp. (780-784), 0950-222X
- Dalma-Weiszhausz, J., Gordon-Angelozzi, M., Ustariz-Gonzalez, O., & Suarez-Licona, A. (2008). Intraocular pressure rise during 25-gauge vitrectomy trocar placement. *Graefes Arch Clin Exp Ophthalmol*, Vol. 246, No. 2, (2008), pp. (187-189), 0721-832X
- De Juan E. Jr & Hickingbotham, D. (1990) Refinements in microinstrumentation for vitreous surgery. *Am J Ophthalmol*, Vol.109, No. 2, (Feb 1990), pp. (218-20), 0002-9394
- Eckardt, CM. (2005) Transconjunctival sutureless 23-gauge vitrectomy. *Retina*, Vol. 25, No. 2, (February/March 2005), pp.(208-11) 0275-004X
- Elrich, R. & Polkinghorn, P. (2011) Small gauge vitrectomy in traumatic retinal detachment. *Clinical and experimental ophthalmology*, Vol. 39, No. 5, (July 2011), pp.(429-433), 1442-6404
- Erakgun T., & Egrilmez S. (2009) Surgical outcomes of transconjunctival sutureless 23-gauge vitrectomy with silicone oil injection. *Indian J Ophthalmol*, Vol. 57, No. 2, (March-April 2009), pp. (105-109), 0301-4738
- Fabian, ID & Moisseiev J. (2011) Sutureless vitrectomy: evolution and current practices. *British Journal of Ophthalmology*, Vol. 95, No. 3, (March 2011), pp.(318-324) 0007-1161
- Fujii GY, de Juan E. Jr, Humayun MS, Pieramici, DJ, Chang, TS, Awh, C., Ng, E., Barnes, A., Wu, SL, & Sommerville, DN. (2002) A new 25-gauge instrument system for transconjunctival sutureless vitrectomy surgery. *Ophthalmology*, Vol. 109, No. 10, (October 2002), pp. (1807-12), 0161-6420
- Gonzales, CR, Boshra J. & Schwartz, SD. (2006) 25-Gauge pars plicata vitrectomy for for stage 4 and 5 retinopathy of prematurity. *Retina* Vol. 26 Suppl 7 (Sept 2006) pp. (S42-S46), 0275-004X
- Gonzales, CR, Singh, S., & Schwartz, SD. (2009). 25-Gauge vitrectomy for peadiatric vitreoretinal conditions. *Br J Ophthalmol*, Vol. 93, No. 6, (June 2009), pp. (787-790), 0007-1161

- Gupta, O., Ho, A., & Kaiser, P. (2008). Short-term outcomes of 23-gauge pars plana vitrectomy. *Am J Ophthalmol*, Vol. 146, (August 2008), pp. (193-197), 0002-9394
- Gupta, OP, Maguire, JI, Eagle, RC, Garg, SJ, & Gonye, GE. (2009). The competency of pars plana vitrectomy incisions: a comparative histologic and spectrophotometric analysis. *Am J Ophthalmol*, Vol. 147, No. 2, (Feb 2009), pp. (243-250), 0002-9394
- Haas, A., Seidel, G., Steinbrugger, I., Maier, R., Gasser-Steiner, V., Wedrich, A., & Weger, M. (2010). Twenty-three-gauge and 20-gauge vitrectomy in epiretinal membrane surgery. *Retina*, Vol. 30, No. 1, (Jan 2010), pp. (112-116), 0275-004X
- Hilton, G. (1985). A sutureless self-retaining infusion cannula for pars plana vitrectomy. *Am J Ophthalmol*, Vol. 99, No. 5, (May 1985), pp. (612), 0002-9394
- Ho, LY, Walsh, MK & Hassan, TS. (2010) 25 Gauge pars plana vitrectomy for retained lens fragments. *Retina*, Vol. 30, No. 6, (June 2010), pp. (843- 849), 0275-004X
- Hsu, J., Chen, E., Gupta, O., Fineman, M., Garg, S., & Regillo, C. (2008). Hypotony after 25-gauge vitrectomy using oblique versus direct cannula insertions in fluid-filled eyes. *Retina*, Vol. 28. No. 7, (July - August 2008), pp. (937-940), 0275-004X
- Hubschman, JP, Gupta, A., Bouri,a DH, Culjat, M., Yu, F., & Schwartz, RD. (2008). 20-, 23-, 25-gauge vitreous cutters: performance and characteristics evaluation. *Retina*, Vol. 28, No. 2, (Feb 2008), pp.(249-257), 0275-004X
- Ibarra, MS, Hermel, M., Prenner, JL, & Hassan, TS. (2005). Longer-term outcomes of transconjunctival sutureless 25-gauge vitrectomy. *Am J Ophthalmol*, Vol. 139, No. 5, (May 2005), pp. (831-836), 0002-9394
- Inoue, M., Noda, K., Ishida, S., Nagai, N., Imamura, Y., & Oguchi, Y. (2004) Intraoperative breakage of a 25-gauge vitreous cutter. *Am J Ophthalmol*, Vol. 138, No. 5, (Nov 2004), pp. (867-869), 0002-9394
- Inoue, M., Shinoda, K., Shinoda, H., Kawamura, R., Suzuki, K., & Ishida, S. (2007). Two-step oblique incision during 25-gauge vitrectomy reduces incidence of postoperative hypotony. *Clin Experiment Ophthalmol*, Vol. 35, No. 8, (Nov 2007), pp (693-696), 1442-6404
- Jackson, T. (2000). Modified sutureless sclerotomies in pars plana vitrectomy. *Am J Ophthalmol*, Vol. 129, No. 1, (Jan 2000), pp. (116-117), 0002-9394
- Kadonosono, K., Yamakawa, T., Uchio, E., Yanagi, Y., Tamaki, Y., & Araie, M. (2006). Comparison of visual function after epiretinal membrane removal by 20-gauge and 25-gauge vitrectomy. *Am J Ophthalmol*, Vol. 142, (Septemper 2006), pp. (513-515), 0002-9394
- Kasner, D. (1969). Vitrectomy: a new approach to management of vitreous. *Highlights Ophthalmol*, Vol. 11, (1969), pp. (304)
- Kiss, S & Vavvas, D. (2008) 25 Gauge sutureless pars plana vitrectomy for removal of retained lens fragments and intraocular foreign bodies. *Retina*, Vol. 28, No.9, (October 2008), pp. (1346-1351), 0275-004X
- Kongsap, P. (2010). Combined 20-gauge and 23-gauge pars plana vitrectomy for the management of posteriorly dislocated lens: a case series. *Clin Ophthalmol*, Vol. 4, (July 2010), pp. (625-628), 1177-5467
- Kunikata, H., Uematsu, M., Nakazawa, T., & Fuse, N. (Feb 2011) Successful removal of large intraocular foreign body by 25 gauge microincision vitrectomy surgery. *Journal of Ophthalmology*, 2090-004X [E pub ahead of print]

- Kunimoto, D. & Kaiser R. (2007). Incidence of endophthalmitis after 20- and 25-gauge vitrectomy. *Ophthalmol*, Vol. 114, (Dec 2007), pp. (2133-2137), 0161-6420
- Leung, L., Nam, W., & Chang, S. (2010) Minimally invasive vitreoretinal surgery, In: *Minimally Invasive Ophthalmic Surgery*, Fine, IH & Mojon, DS, pp (217-225) Springer, 978-3-642-02601-0, Heidelberg, Germany
- Lopez-Guajardo, L., Pareja-Esteban, J., & Teus-Guezala, MA. (2006). Oblique sclerotomy technique for prevention of incompetent wound closure in transconjunctival 25-gauge vitrectomy. *Am J Ophthalmol*, Vol. 141, (June 2006), pp. (1154-1156), 0002-9394
- Machemer, R. (1995) The development of pars plana vitrectomy: a personal account. *Graefes Arch Clin Exp Ophthalmol.*, Vol. 233, No. 8, (Aug 1995), pp.(453-68), 0721-832X
- Machemer R., & Hickingbotham D. (1985). The three-port microcannular system for closed vitrectomy. *Am J Ophthalmol*, Vol. 100, (October 1985), pp. (590-592), 0002-9394
- Mangalhaes, O., Chong, L., DeBoer, C., Bhadri, P., Kerns, R., Barnes, A., Fang, S., Schor, P., & Humayun, M. (2009). Guillotine performance: duty cycle analysis of vitrectomy systems. *Retinal Cases & Brief Reports*, Vol. 3, No. 1, (Winter 2009), pp. (64-67), 1935-1089
- Magalhaes, O Jr., Maia, M., Rodrigues, EB, Machado, L., Costa, EF, Maia, A., Moares-Filho, MN, Dib, E., & Farah, ME. (2011) Perspective on fluid and solid dynamics in different pars plana vitrectomy systems. *American Journal of Ophthalmology*, Vol. 151 No.3, (March 2011) pp. (401-405e.1), 0002-9394
- Mitra, RS & Pollak, JS. (2007). Preference and Trends Survey. Poster presented at: 25th Annual American Society of Retina Specialists Meeting, December 1-5, 2007; Indian Wells, CA). <http://www.asrs.org>; access for members only.
- Misra, A., Ho-Yen, G., & Burton, RL. (2009). 23-gauge sutureless vitrectomy and 20-gauge vitrectomy: A case series comparison. *Eye*, Vol. 23, No. 5, (May 2009), pp. (1187-1191), 0950-222X
- O'Malley C., & Heintz R. (1975). Vitrectomy with an alternative instrument system. *Ann Ophthalmol*, Vol. 7, (April 1975), pp. (585-594), 0003-4886
- Oshima, Y., Wakabayashi T., Sato, T, Ohji, M., & Tano, Y. (2010) A 27-gauge instrument system for transconjunctival sutureless microincision vitrectomy surgery. *Ophthalmology*, Vol. 117, No. 1 (January 2010), pp. (93-e102.e2), 0161-6420
- Peyman, GA. (1990) A miniaturized vitrectomy system for vitreous and retinal biopsy. *Can J Ophthalmol*, Vol. 25, No. 6, (Oct 1990), pp. (285-6), 0008-4182
- Recchia, F., Reichstein DA, & Kammer, JA. (2010). Small gauge vitrectomy in combination with glaucoma implant procedures. *Retina*, Vol. 30, No. 7, (July- August 2010), pp. (1152-54), 0275-004X
- Recchia, FM, Scott, IU, Brown, GC, Brown, MM, Ho, AC, & Ip, MS. (2010) Small gauge pars plana vitrectomy. A report by the American Academy of Ophthalmology. *Ophthalmology*, Vol. 117, No. 9, (September 2010) pp. (1851-57), 0161-6420
- Rizzo, S., Genovesi-Ebert, F., Murri, F., Belting, C., Vento, A., Cresti, F., & Manca, ML. (2006) 25-gauge sutureless vitrectomy and standard 20-gauge pars plana vitrectomy in idiopathic epiretinal membrane surgery: a comparative pilot study. *Graefes Arch Clin Exp Ophthalmol*, Vol. 244, (April 2006), pp. (472-479), 0721-832X
- Rizzo, S., Patelli, F., Chow, DR. (2009). Essentials in Ophthalmology: *Vitreo-Retinal Surgery, Progress III*. Springer, ISBN 978-3-540-69461-8, Verlag, Berlin, Heidelberg, Germany

- Rizzo, S., Beltling, C., Genovesi-Ebert, F., & Bartolo, E. (2010). Incidence of retinal detachment after small-incision, sutureless pars plana vitrectomy compared with conventional 20-gauge vitrectomy in macular hole and epiretinal membrane surgery. *Retina*, Vol. 20, No. 7, (July- August 2010), pp. (1065-1071), 0275-004X
- Rodrigues EB, Meyer, CH, Mennel, S., & Farah, ME. (2007). Mechanisms of intravitreal toxicity of indocyanine green dye: implications for chemovitrectomy. *Retina*, Vol. 27, No. 7, (Sep 2007), pp. (958-970), 0275-004X
- Rossi, T., Boccassini, B., Iossa, M., Lesnoni, G., & Tamburrelli, C. (2010) Choroidal hemorrhage drainage through 23 gauge vitrectomy cannulas. *Retina*, Vol. 30 No. 1, (January 2010), pp(174-176), 0275-004X
- Schweitzer, C., Delyfer MN, Colin, J., & Korobelnik, JF. (2009) 23 gauge transconjunctival sutureless pars plana vitrectomy: results of a prospective study. *Eye*, Vol. 23, No. 12, (December 2009), pp. (2206-2214), 0950-222X
- Scott, IU, Flynn, HW, Acar, N., Dev, S., Shaikh, S., Mitra RA, Arevalo, JF, Kychenthal, A., & Kunselman, A. (2011). Incidence of endophthalmitis after 20-gauge vs 23-gauge vs 25-gauge pars plana vitrectomy. *Graefes Arch Clin Exp Ophthalmol*, Vol. 249, No. 3, (Mar 2011), pp. (377-380), 0721-832X
- Shimada, H., Nakashizuka, H., Mori, R., Mizutani, Y., & Hattori, T. (2006). 25-gauge scleral tunnel transconjunctival vitrectomy. *Am J Ophthalmol*, Vol. 142, (November 2006), pp. (871-873), 0002-9394
- Shimada, H., Nakashizuka, H, Hattori, T., Mori, R., Mizutani, Y., & Yuzawa, M. (2008). Incidence of endophthalmitis after 20- and 25-gauge vitrectomy. *Ophthalmol*, Vol. 115, (December 2008), pp. (2215-2220), 0161-6420
- Singh, A., Chen, JA, & Stewart, JM. (2008). Ocular surface fluid contamination of sutureless 25-gauge vitrectomy incisions. *Retina*, Vol. 28, No. 4, (April 2008), pp. (553-557), 0275-004X
- Singh, RP, Bando, H., Brasil, OF, Williams, DR, & Kaiser, PK. (2008). Evaluation of wound closure using different incision techniques with 23-gauge and 25-gauge microincision vitrectomy systems. *Retina*, Vol. 28, No. 2, (Feb 2008), pp. (242-248), 0275-004X
- Taban, M., Sharma, S., Ventura, A., & Kaiser, PK. (2009). Evaluation of wound closure in oblique 23-gauge sutureless sclerotomies with visante optical coherence tomography. *Am J Ophthalmol*, Vol. 147, No. 1, (Jan 2009), pp (101-107), 0002-9394
- Thompson, JT. (2011) Advantages and limitations of small gauge vitrectomy. *Survey of ophthalmology*, Vol. 56, No. 2, (March- April), pp. (162-71), 0039-6257
- Trikha, R., Yeung, CC, Modjtahedi, SP & Telander, DG. (2010) Evaluation of 25 gauge and 20 gauge vitrectomy on cell viability and diagnostic yield for B-cell lymphoma in culture using flow cytometry. *Retina*, Vol. 30, No. 9, (Oct 2010), pp. (1505-1510), 0275-004X
- Warrier, SK, Jain, R., Gilhotra, JS, Newland, HS. (2008). Sutureless Vitrectomy. *Indian J Ophthalmol*, Vol 56, (November- December 2008), pp. (453-458), 0301-4738
- Williams, GA. (2008) 25-, 23-, or 20-gauge instrumentation for vitreous surgery. *Eye*, Vol. 22, No. 10, (October 2010), pp. (1263-1266), 0950-222X
- Williams, GA & Drenser, K. (2009) Epiretinal membrane surgery, In: *Surgical techniques in ophthalmology retina and vitreous surgery*, Bhavsar, AR, pp. (65-70) Saunders 978-1-4160-4206-8

- Wong, RW, Kokame, GT, Mahmoud, TH, Mieler, WF, Tornambe, PE & McDonald, HR. (2010). Complications associated with clear corneal cataract wounds during vitrectomy. *Retina*, Vol. 30, No. 6, (June 2010), pp. 850-855, 0275-004X
- Woo, SJ, Park, KH, Hwang, JM, Kim, JH, Yu, YS, & Chung, H. (2009). Risk factors associated with sclerotomy leakage and postoperative hypotony after 23-gauge transconjunctival sutureless vitrectomy. *Retina*, Vol. 29, No. 4, (Apr 2009), pp. (456-463), 0275-004X
- Wu P., Tiong, IS, Chuang, YC, & Kuo, HK (2011). Twisting maneuver for sutureless vitrectomy trocar insertion to reduce intraoperative intraocular pressure rise. *Retina*, Vol. 31, No. 5, (May 2011), pp. (887-892), 0275-004X
- Yeh, S., Weichel, E., Faia, LJ, Albini, TA, Wroblewski, KK, Stetler-Stevenson, M., Ruiz, P, Sen, HN, Chan, CC, & Nussenblatt, RB . (2010) 25- gauge transconjunctival sutureless vitrectomy for the diagnosis of intraocular lymphoma. *British Journal of Ophthalmology*, Vol. 94, No. 5, (May 2010), pp. (633-638) 0007-1161



Vitrectomy

Edited by Dr. Zongming Song

ISBN 978-953-51-0546-6

Hard cover, 96 pages

Publisher InTech

Published online 20, April, 2012

Published in print edition April, 2012

This book is a comprehensive and systematic introduction to the basic theory, surgical techniques and the latest advances in vitrectomy. It focuses on vitreoretinal surgical indications and contraindications, surgical and operating techniques, surgery-related complications and their prevention, post-operation evaluation and prognosis. The book is divided into 6 chapters and has abundant content as well as a strong scientific and practical value. This book will be a valuable reference to ophthalmologists on all levels, especially vitreoretinal surgeons and researchers.

How to reference

In order to correctly reference this scholarly work, feel free to copy and paste the following:

Rupan Trikha, Nicole Beharry and David G. Telander (2012). Small Gauge Pars Plana Vitrectomy, Vitrectomy, Dr. Zongming Song (Ed.), ISBN: 978-953-51-0546-6, InTech, Available from:
<http://www.intechopen.com/books/vitrectomy/small-gauge-pars-plana-vitrectomy>

INTECH

open science | open minds

InTech Europe

University Campus STeP Ri
Slavka Krautzeka 83/A
51000 Rijeka, Croatia
Phone: +385 (51) 770 447
Fax: +385 (51) 686 166
www.intechopen.com

InTech China

Unit 405, Office Block, Hotel Equatorial Shanghai
No.65, Yan An Road (West), Shanghai, 200040, China
中国上海市延安西路65号上海国际贵都大饭店办公楼405单元
Phone: +86-21-62489820
Fax: +86-21-62489821

© 2012 The Author(s). Licensee IntechOpen. This is an open access article distributed under the terms of the [Creative Commons Attribution 3.0 License](https://creativecommons.org/licenses/by/3.0/), which permits unrestricted use, distribution, and reproduction in any medium, provided the original work is properly cited.